

**HISTOLOGICAL, HISTOCHEMICAL AND SERUM PROTEIN ELECTROPHORESIS STUDY ON THE EFFECT OF PARACETAMOL AND CAFFEINE COMBINATION ON FEMALE RAT LIVER.**

---

MOHAMED I. RADY

*Department of Zoology, Faculty of Science, Al-Azhar University*

---

**Abstract**

This study aimed to evaluate the histochemical changes in the liver and protein changes in the serum, induced by combination of paracetamol (analgesic and antipyretic drug) and caffeine in female rats.

Female rats were divided into four groups, the first group served as control, the second received multiple oral doses of paracetamol and caffeine (125 and 20 mg/kg bw, respectively), the third group received oral dose of paracetamol and caffeine (250 and 40 mg/kg bw, respectively) and the fourth received oral dose of paracetamol and caffeine (500 and 75 mg/kg bw, respectively). The treatment lasted for four weeks.

The obtained results showed that this combination caused different histological changes and caused significant diminutions in the contents of total protein, nuclear DNA and esterase enzyme in the liver. Also the treatments with this combination discomfort the normal protein patterns of serum in comparison with control. These effects were evidently dose dependent. These results support the suggestion that the previously known effect of the analgesic drug may be enhanced with caffeine administration.

**Introduction**

Paracetamol (acetaminophen) is one of the most widely used drugs extensively prescribed as anti-inflammatory, analgesic and antipyretic (Kastrup and Olin, 1987). Caffeine is considered as one of the compounds most widely consumed by the world population, it is a central nervous system stimulant used in several pharmaceutical compounds and as a constituent of foods (Felipo *et al.*, 1986). Because of the widespread use of these drugs, any unintended effect could have serious adverse public health consequences (De-Kun *et al.*, 2003).

Several animal and human studies on hepatotoxicity (Rady, 2001 and Gill *et al.*, 2002) induced by exposure to different drugs have been done. The latter authors added that the combination of acute fatty liver and acetaminophen toxicity resulted in acute liver failure. Also, caffeine injection resulted in slight increase in absolute and relative liver weight denoting considerable enlargement in the organ in spite of

the loss in total body weight (Daubert, 1976). Mitchell *et al.* (1973) administered one dose of 375 mg/kg paracetamol ip. to mice and found liver necrosis in 45% of the animals examined. Also, combined effects of acetaminophen and caffeine on pregnant and non-pregnant rats were studied by Burdan *et al.* (2001, b) and Burdan (2003).

The effects of different drugs single or in combination on the histochemistry of the liver of experimental animals have been documented (Burdan *et al.*, 2001a and Marrif *et al.*, 2003). Also, Janson and Ryden (1989) declared that fundamental to electrophoretic separations is the fact that proteins are electrically charged particles in addition the proteins often have associated charged components of non-protein origin. EPA (1990) reported that protein adducts can be used as biomarkers of chemicals exposure.

Accordingly, this work was designed to study the effects of combination of paracetamol and caffeine on the liver including histological and histochemical changes as well as protein patterns of the serum in female rats.

### **Materials And Methods**

This work was carried out on female albino rats, *Rattus norvegicus*, with average body weight of  $150 \pm 20$  gm. These animals were obtained from Egyptian Organization for Vaccine and Biological preparation at Helwan. They were marked and housed in cages in the laboratory at room temperature and fed on a standard rodent pellet manufactured by Egyptian Company for Oil and Soap as well as some vegetables as a source of vitamins, also water was supplied *ad libitum*.

Female rats were divided into four groups, each group contained 10 rats, the first group (GI) served as control, the second (GII), third (GIII) and fourth (GIV) were treated with combination of paracetamol (acetaminophen) and caffeine for four weeks. GII received daily oral combined dose of paracetamol and caffeine (125 mg/kg and 20 mg/kg, respectively), GIII received daily oral dose of paracetamol and caffeine (250 mg/kg and 40mg/kg, respectively). The fourth group (GIV) received daily oral dose of paracetamol and caffeine (500 mg/kg and 75 mg/kg, respectively). These doses were chosen according to Burdan *et al.* (2001, a). At the end of experimentation, rats were anesthetized with ether; specimens of liver from the four groups were used in histological and histochemical investigations. Blood was collected in centrifuge tubes and left for ½ hour, and then sera were separated and stored at  $-4^{\circ}\text{C}$ .

*Histological and histochemical investigations:*

For study of the histological and histochemical changes, specimens of the liver were fixed in neutral formalin. Then the fixed tissues were subsequently processed for microtomy at 6 $\mu$  thickness. For study of the histological changes, routine haematoxylin and eosin liver sections were made. For visualization of total proteins, the mercury bromphenol blue method of Mazia *et al.* (1953) was applied. Feulgen reaction method for DNA demonstration (Pearse, 1972) was used. For demonstration of non-specific esterases activity in the liver, frozen sections were made using cryostat according to the method described by Gomori (1952).

The histochemical interpretation was done using computer image analyzing system (Leica Model). Estimation of the optical density of thirty cells in each group was made. The data obtained were statistically analyzed according to Sendecor (1987). Differences between the group means were assessed using t-test.  $P \leq 0.05$  was considered significant, and the percentage of change was calculated as follows:

$$\% \text{ =Percentage of change} = \frac{\text{Data of treated} - \text{Data of control}}{\text{Data of control}} \times 100$$

*Electrophoresis investigation:*

The protein fractions of serum of control and treated groups were separated using sodium dodecyle sulfate polyacrylamide gel electrophoresis (SDS-PAGE) according to the method described by Stgemann *et al.* (1988). Molecular weight of different proteins were determined using standard sigma proteins marker (wide range cat # 4038).

**Results**

The normal histological structure of control female rat liver is presented in figure (1). Liver sections obtained from rats belonging to GII showed slight histopathological changes in the hepatic tissue. These changes were manifested in lymphocytic infiltration around the blood vessels, and slight congestion in blood vessels (Fig.2). Also Kupffer cells were greatly encountered and they were hypertrophied in different areas of the hepatic tissue. Most of the hepatocytes were approximately similar to those of control animals with eosinophilic cytoplasm. Combination of paracetamol and caffeine for four weeks (in daily dose equal 250 mg/kg and 40 mg/kg) resulted in dilated and congested blood vessels and slight areas of haemorrhage. Also some pyknotic nuclei, increased number of Kupffer cells and macrophages were noticed (Figs. 3 and 4).

Inspected liver sections obtained from GIV (500 mg and 75 mg/kg b w, paracetamol and caffeine respectively) displayed necrobiotic changes in the hepatocytes. Pyknotic nuclei, karyolysis and even necrotic cells were perceptible (Figs. 5 and 6). In other parts of the liver tissue, hydropic degeneration and vacuolation in the hepatocytes, complete degenerated hepatocytes and oedematous blood vessels were ratified.

Combination of paracetamol and caffeine induced reduction in the total protein of the liver in female rats in a dose dependent manner. This reduction was non significant in GII and GIII but significant in GIV. The percentage of reduction reached 7.477%, 12.068% and 28.856% in GII, GIII and GIV respectively, as compared with control (Table 1). Figures 7- 10 represent the total protein contents in the liver of control and treated groups. The measurements of DNA content in the liver cells revealed significant reduction in all treated groups (Figs. 11-14); the highest reduction was recorded in GIV, being 37.610% while the lowest was recorded in GII, being 18.912%, when compared with control. The activity of the esterase enzyme was affected by the treatment with paracetamol and caffeine combination (Figs. 15- 18). The liver cells of groups III and IV showed significant reduction in esterase activity, while GII recorded non significant reduction. The percentages of reduction were 8.045%, 27.976% and 24.481% in GII, GIII and GIV respectively.

The results of the SDS-PAGE gel of sera proteins for control and treated rats are presented in figure (19) and table (2). The obtained results revealed that the exposure to paracetamol and caffeine combination for four weeks decomposed the normal pattern of the serum protein in treated animals.

The most changes induced in the serum proteins were represented in changes in the intensity of the major protein bands and appearance of some new bands, in GII and GIV. The number of bands in group post exposure to 125 mg/kg and 20 mg/kg, paracetamol and caffeine, respectively, recorded 17 bands, while in groups post exposure to 500 mg/kg and 75 mg/kg paracetamol and caffeine respectively the number of recorded was 20 bands. The number of bands in TIII recorded the same number as control.

The most changes in the protein band intensity were mostly found in a molecular weight area between 66 and 29 K Dt. Also the new bands that appeared post treatment with this combination were found in a low molecular weight area, being between 36 and 14 K Dt, approximately. The percentages of similarity between control and each of the treated groups are presented in figure (20). The highest

percentage of similarity was recorded in GIII being 89.8%, while the lowest percentage was recorded in GIV being 79.73%. The dissimilarity between control and GII reached 17.58%.

### **Discussion**

Non steroidal anti-inflammatory drugs represent one of the most highly utilized classes of pharmaceutical agents in medicine. Several reports have indicated that, using of most drugs, including analgesic drugs, were usually accompanied with hepatotoxic effect in different experimental animals as well as human (Gill *et al.*, 2002; Burdan, 2003; Marrif *et al.*, 2003 and Simmons *et al.*, 2004). The present study showed that treatment with combination of paracetamol and caffeine for four weeks induced different histological and histochemical effects that were increased according to the increase dose in the liver of female rats, *Rattus norvegicus*.

The histological changes in the liver of female rats were mainly found with the middle and high dose of the combination treatment in the present study. These changes were represented in congestion and dilatation in blood vessels, haemorrhage and lymphocytic infiltration. These effects were increased in GIV where hydropic degeneration, oedematous blood vessels and necrobiotic changes were perceptible. In coincidence, Laub *et al.* (2000) reported that paracetamol administration in high doses induced significant decreases in the antioxidant level of the liver of female mice which promote the increase of the free radicals generated by the drug causing hepatotoxicity. Also, Sato and Isumi (1989) and Farag and Abdel-Meguid (1994) discussed that paracetamol enhanced the caffeine depleted antioxidants to a greater extent. In agreement with the present findings, Wahba and Ziada (1992) similarly reported that combination of caffeine and nicotine administered to rats resulted in degeneration in the hepatocytes. Riordan and Williams (2002) reported that at low doses of paracetamol a reduced hepatic content of antioxidant, required to detoxify the reactive metabolites, has been pointed out.

Degeneration and necrosis of the hepatic cells following paracetamol and caffeine combination treatment could be explained according to the suggestion of Ritter (1977). He reported that liver cell necrosis may be either due to progressive degenerative action of intracellular enzymes of the injured cells or to a metabolic disturbance and inhibition of synthesis needed of DNA and hence protein synthesis for the growth and maturation of the liver.

Drug metabolism system can be induced or activated by a large number of exogenous agents including drug, alcohol, components in the diet and caffeine as

well as endogenous factors (Park *et al.*, 1996). The histochemical investigations in the present work showed that the treatment with paracetamol and caffeine in combination caused significant reduction in the total protein in GIV and non significant in GII and GIII. Also the present results revealed significant diminution of DNA content of the hepatocytes in all treated groups and significant reduction in the activity of the non specific esterase enzyme in GIII and GIV. Similar effects of paracetamol and caffeine on the liver of experimental animals have been documented by many authors (Schlegel *et al.*, 1987; Lehmann *et al.*, 1996 and Burdan *et al.*, 2001a and b). Keith and Weber (1979) suggested that reduced protein could be attributed to several pathological processes including plasma dissolution, renal damage and elimination in the urine, decreased liver protein synthesis, alteration in hepatic blood flow and/or haemorrhage.

However, Rocha *et al.* (2001) declared that caffeine greatly potentiated the effect of paracetamol, pointing to a potential danger of the mixture. They added that paracetamol inhibited the synthesis of DNA and caused chromosomal aberration due to inhibition of ribonucleotide reductase. Harman (1983) suggested that the accumulation of free radicals, generated by the drug, in the cells attacked DNA and led to cross-linkage with the molecule resulting in reduction of its biological activity.

Park *et al.* (1996) reported that the toxicological implication will be determined either by change in the route of metabolism or by a disturbance of the balance between activation and detoxication processes which may be isozyme selective. Burdan *et al.* (2001a) noted that combination of paracetamol and caffeine induced significant decreases in total protein, aminotransferase, alanine transaminase, glucose-6-phosphatase and glutamate dehydrogenase in the liver of rats. The present results exhibited significant decreases of the liver esterase activity in both GIII and GIV and non significant decrease in GII post four weeks of the treatments with paracetamol and caffeine combination. Broughan and Soloway (2000) mentioned that paracetamol overdose induced hepatic toxicity in human through the elevation in the transaminase level in plasma. Also, the necrosis and degeneration in the tissue following drug treatment were usually secondary to those of free radicals which had damaging effects on the cell membrane and led to release of enzymes (O'Brien *et al.* 2000).

Chromatographic separations in conjunction with physical and chemical detection method can provide extremely accurate and highly precise of drugs in biological matrices (Evenson and Wiktorowicz, 1992). Electrophoresis studies on

the chronic oral toxicity of an analgesic drug combination consisting of acetylsalicylic acid, paracetamol and caffeine in rat demonstrated several protein changes resulting from caffeine treatment (Lehmann *et al.*, 1996). In coincidence, the present study revealed that the exposure to paracetamol and caffeine combination induced changes in the intensity of the major proteins of the serum of treated animals and aroused the appearance of new protein bands, which suggest that this combination induced protein adduct, these changes were mostly found in a low molecular weight area of SDS-PAGE. The appearance of new proteins due to different chemical treatments in these areas of the gel was also evident by many authors as sensitive proteins (Dutta *et al.*, 1992 and Abou Zeid, 1995). Also, Hinson *et al.* (1998) proved that paracetamol hepatotoxicity was associated with increased expression of nitric oxide synthase and formation of nitrotyrosine-protein adducts.

**Table (1): Statistical analyses of the quantitative measurements of total protein (Bromophenol blue stain), DNA (Feulgen reaction) and esterase enzyme (Gomori method) in the liver cells of control and treated groups.**

		Control (GI)	GII	GIII	GIV
Total protein	Average	1.102	1.0196	0.969	0.784
	SD	0.17964	0.165659	0.163245	0.156749
	SE	0.08034	0.074087	0.073008	0.070102
	t test		0.147596	0.086257	0.001803
	Probability		N.S.	N. S.	S.
	%of change		-7.477	-12.068	-28.856
DNA	Average	1.2172	0.987	0.8554	0.7594
	SD	0.332523	0.198754	0.09823	0.088344
	SE	0.148713	0.088888	0.043931	0.03951
	t test		0.003237	0.002531	0.001402
	Probability		S.	S.	S.
	%of change		-18.912	-29.723	-37.610
Esterases	Average	1.0416	0.9578	0.7502	0.7866
	SD	0.079829	0.073128	0.13684	0.171884
	SE	0.035702	0.032705	0.061198	0.076871
	t test		0.163915	0.000109	0.003219
	Probability		N.S.	S.	S.
	%of change		-8.045	-27.976	-24.481

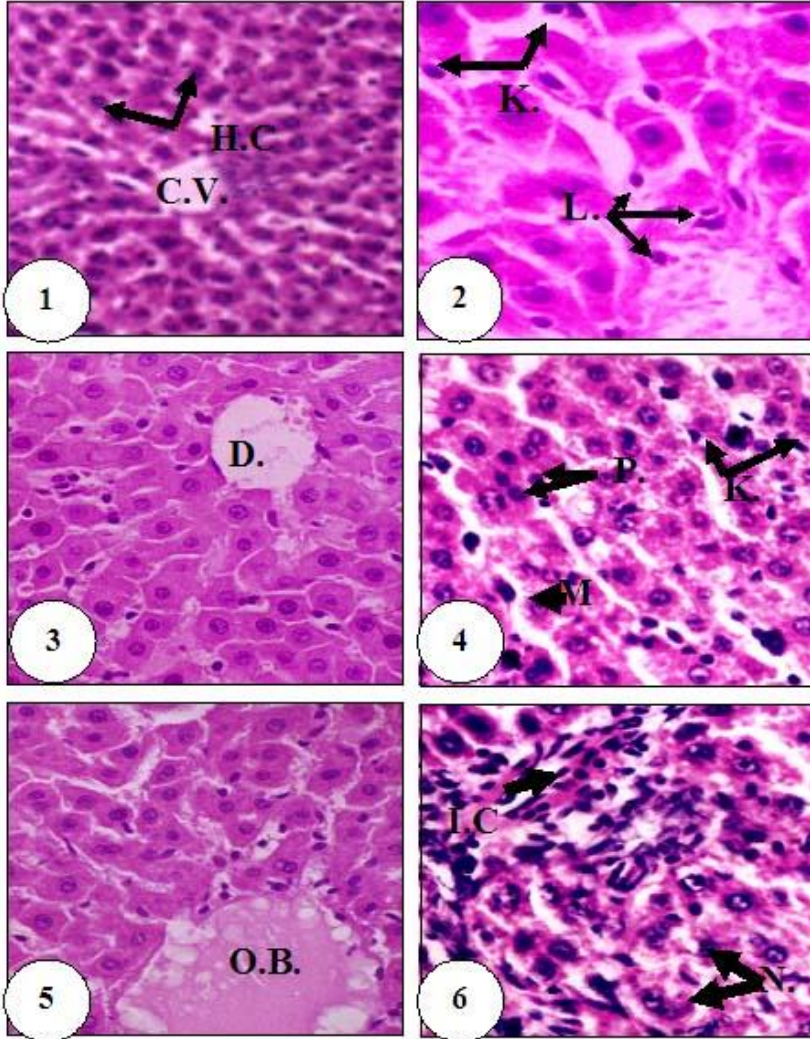


Fig. (1): Liver section of control female rat showing normal structures, central vein (C.V.) and hepatic cords (H.C.). (H/E X 250).

Fig. (2): Liver section of female rat of GII showing Kupffer cells (K.) and increase number of lymphocytes (L.). (H/E X 400).

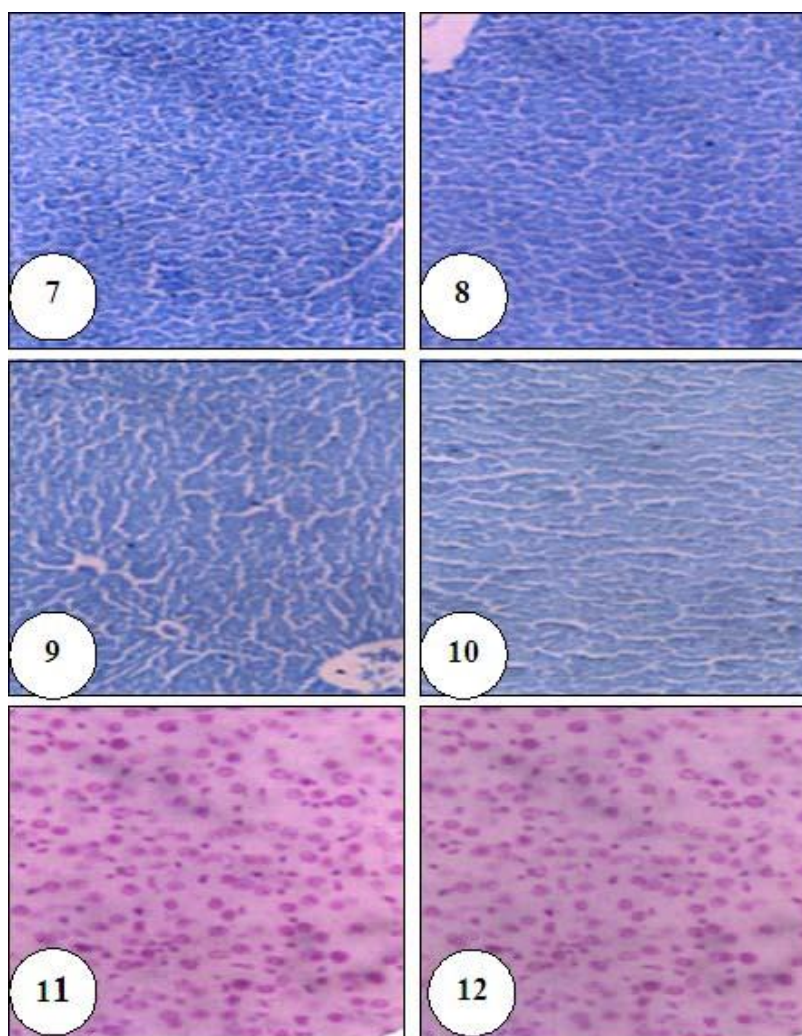
Fig. (3): Liver section of female rat of GIII showing dilated blood vessel (D.B.) and swelling in the hepatocytes. (H/E X 250).

Fig. (4): Liver section of female rat of GIII showing pyknotic nuclei (P.), macrophage (M.) and increase of Kupffer cells number (K.). (H/E X 400).

Fig. (5): Liver section of female rat of GIV showing oedematous blood vessels (O.B.V.). (H/E X 250).

Fig. (6): Liver section of female rat of GIV showing infiltration of lymphocytes (I.C.) and necrotic cells (N.). (H/E X 400).





**Fig. (7):** Liver section of control female rat showing the normal content of total protein. (Bromphenol blue X 250).

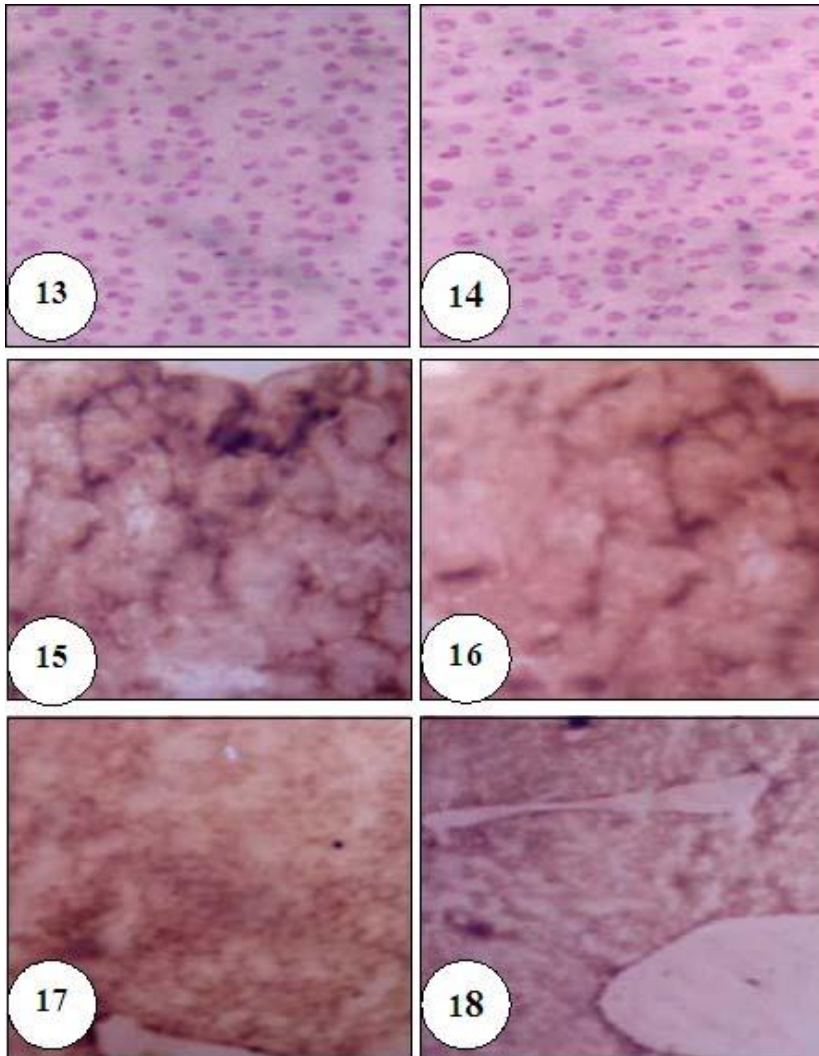
**Fig. (8):** Liver section of female rat of GII showing slight reduction in the total protein content. (Bromphenol blue X 250).

**Fig. (9):** Liver section of female rat of GIII showing slight reduction in the total protein content. (Bromphenol blue X 250).

**Fig. (10):** Liver section of female rat of GIV showing obvious reduction in the total protein content. (Bromphenol blue X 250).

**Fig. (11):** Liver section of control female rat showing the normal content of the nuclear DNA. Feulgen reaction X 400).

**Fig. (12):** Liver section of female rat of GII showing the nuclear DNA content is reduced. (Feulgen reaction X 400).



**Fig. (13):** Liver section of female rat of GIII showing the nuclear DNA content is reduced. (Feulgen reaction X 400).

**Fig. (14):** Liver section of female rat of GIV showing the nuclear DNA content is prominently reduced. (Feulgen reaction X 400).

**Fig. (15):** Liver section of control female rat showing the normal activity of the esterase's enzymes. (Gomori method X 250).


**Fig. (16):** Liver section of female rat of GII showing decrease activity of the esterase's enzymes. (Gomori method X 250).

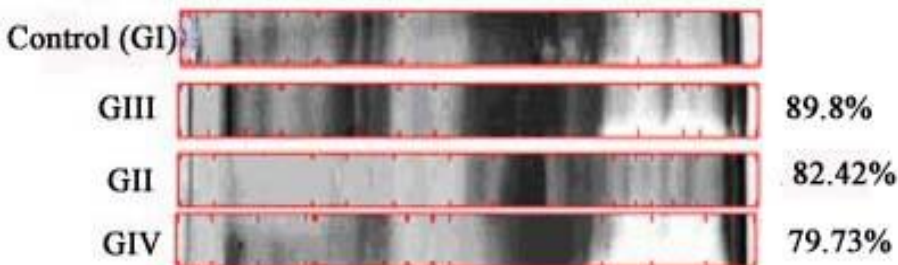
**Fig. (17):** Liver section of female rat of GIII showing pronounced decrease activity of the esterase's enzymes. (Gomori method X 250).

**Fig. (18):** Liver section of female rat of GIV showing prominent decrease activity of the esterase's enzymes. (Gomori method X 250).

**Table (2): The percentage of intensity and migration distance of serum protein bands of control and treated groups.**

Band No.	M. D. (cm.)	Control (GI)	GII	GIII	TIV	Standard Mol. W. (kDt)
1	0.23	2.9	3.4	3.5	6.6	----
2	0.48	0.7	1.7	0.9	2.8	205
3	0.60	0.8	3.4	0.7	5.2	----
4	0.92	2.2	3.0	1.7	3.2	----
5	1.12	1.7	1.7	1.6	2.1	116
6	1.53	5.6	2.7	4.6	3.5	----
7	1.85	5.0	1.2	5.3	1.2	97
8	2.25	3.6	7.5	2.9	7.6	94
9	3.11	9.3	30.0	1.2	25.4	66
10	3.98	25.1	17.2	7.2	7.0	55
11	4.54	18.2	2.6	28.8	8.4	45
12	4.93	----	2.7	----	1.6	36
13	5.27	2.7	3.0	18.8	4.2	29
14	5.61	----	----	----	1.9	----
15	5.97	5.5	1.9	3.8	1.3	24
16	6.23	-----	----	----	1.4	20
17	6.58	-----	----	----	3.2	----
18	6.90	2.4	14.3	2.8	6.7	14
19	7.30	13.4	1.4	0.7	3.0	----
20	7.76	0.9	2.3	15.5	3.7	6.5

**Figure (19): Photographic picture of the gel electrophoresis of serum proteins of female rats, Control (GI), treated groups and standard (St).**



**Figure (20): Similarity percentages among the serum protein lanes of control and treated groups.**

### References

1. ABOU ZEID, M. M. (1995): Serum protein profile: A possible biomarker for exposure to environmental pollutants. *J.Fac.Education, Ain Shams Univ.* Vol. 20: 503-517.
2. BROUGHAN, T.A. AND SOLOWAY, R. D. (2000): Acetaminophen hepatotoxicity. *Dig. Dis. Sci.*; 45 (8): 1553- 1558.
3. BURDAN, F.; SIEZIENIEWSKA, Z. AND URBANOWICZ, Z. (2001a): Combined effects of acetaminophen, isopropylantipyrine and caffeine on pregnant and nonpregnant liver. *Hum Exp Toxicol.*; 20(11): 569-75.
4. BURDAN, F.; SIEZIENIEWSKA, Z.; KIS, G. AND BLICHARSKI, T. (2001b): Embryofoetotoxicity of acetaminophen and caffeine in experimental in vivo model. *Ann. Univ. Mariae Curie Sklodowska*; 56: 89- 94.
5. BURDAN, F. (2003): Intrauterine growth retardation and lack of teratogenic effects of prenatal exposure to the combination of paracetamol and caffeine in Wistar rats. *Reprod Toxicol.*; 17(1): 51-58.
6. DAUBERT, B. F. (1976): Effect of long-term administration of coffee and caffeine in rats. 3<sup>rd</sup> International Colloquium on Chemistry of Coffee. A.S.I.C., Paris, pp 387- 388.
7. DE-KUN, L., LIYAN, L. AND ROXANA, O. (2003): Exposure to non-steroidal anti-inflammatory drugs during pregnancy and risk of miscarriage: population based cohort study. *Int. J. Archive of Disease in Childhood*; 327:368.
8. DUTTA, H. M.; DOGRA, J. V. V.; SINGH, N. K.; ROY, P. K.; NASAR, S. S. T.; ADHIKARI, S.; MUNSH, J. S. D. AND RICHMONDS, C.(1992): Malathion induced changes in the serum protein and haematological parameters of an Indian catfish, *Heteropneustes fossilis* (Bloch). *Bull. Environ. Contam. Toxicol.*; 49: 91- 97.

9. EPA (1990): Protein adduct forming chemicals for exposure monitoring: Literature summary and recommendations. (By Schnell, F.C. and Chiang, T.C.). U.S. Environ. Prot. Age. pp. 134.
10. FELIPO, V.; PORTOLES, M.; MINANA, M.D. AND GRISOLIA, S. (1986): Rats that consume caffeine show decreased brain protein synthesis. *Neurochemical Research*; 11(1): 63- 69.
11. EVENSON, M.A. AND WIKTOROWICZ, J.E. (1992): Automated capillary electrophoresis applied to therapeutic drug monitoring. *Clin. Chem.*; 38(9): 1847- 1852.
12. FARAG, M.M. AND ABDEL-MEGUID, E.M. (1994): Hepatic glutathione and lipid peroxidation in rats treated with theophylline. Effect of dose and combination with caffeine and acetaminophen. *Biochem. Pharmacol.*:47(3): 443-446.
13. GILL, E.; CONTOS, M. AND PENG, T. (2002): Acute fatty liver of pregnancy and acetaminophen toxicity leading to liver failure and postpartum liver transplantation. A case report. *J. Reprod. Med.*; 47(7): 584- 587.
14. GOMORI, G. (1952): *Microscopical histochemistry*. Chicago University, USA.
15. HARMAN, D. (1983): Free radical theory of aging consequences of mitochondrial aging. *Age*; 6: 86-94.
16. HINSON, J.A.; PIKE, S.L.; PUMFORD, N.R. AND MAYEUX, P.R. (1998): Nitrotyrosine-protein adducts in hepatic centrilobular areas following toxic doses of acetaminophen in mice. *Chem. Res. Toxicol.*; 11: 604-607.
17. JANSON, J. and RYDEN, L. (1989): *Protein purification: Principles, high resolution methods and applications*. 1<sup>st</sup> Ed. VCH Pub. Inc. 220 East 23<sup>rd</sup> street Suite 909, New York.
18. KASTRUP, E. K. and OLIN, B. R. (1987): *Drug facts and comparisons*. J. B. Lippincott Company Philadelphia. pp 501- 575.
19. KEITH, F.P. and WEBER, J. L. (1979): The effect of carbon tetrachloride on the total plasma protein concentration of rainbow trout, *Salmo gairdneri*. *Comp. Biochem. Physiol.* Vol. 63(C): 37- 42.
20. LAUB, D. N.; ELMAGBARI, N.; ELMAGHARI, N.; HAUSBURG, M. AND GARDINER, C. S. (2000): Effect of acetaminophen on preimplantation embryo glutathione concentration and development in vivo and in vitro. *Toxicol. Sci.*; 56(1): 150-155.
21. LEHMANN, H.; HIRSCH, U.; BAUER, E.; BAUER, M.; GREISHEL, A.; SCHMID, J. AND SCHNEIDER, P. (1996): Studies on the chronic oral toxicity of an analgesic drug

- combination consisting of acetylsalicylic acid, paracetamol and caffeine in rats including an electron microscopical evaluation of kidneys. *Arzneimittelforschung*; 46(9): 895-905.
22. MARRIF, H.I.; ALI, B.H. AND BASHIR, A.A. (2003): The effect of lorazepam and flumazenil on some hepatic unction in mice. *Ind. J. Pharmacol.*; 35: 392-394.
23. MAZIA, D.; BREWER,P.A. AND AFFERT, M. (1953): The cytochemical staining and measurement of protein with mercuric bromphenol blue. *Biol. Bull.* ; 104: 57-67.
24. MITCHELL, J. R.; JOLLOW, D. J.; POTTER, W. Z.; GILLETTE, J. R. AND BRODIE, B. B. (1973): Acetaminophen-induced hepatic necrosis: IV. Protective role of glutathione. *J. Pharmacol. Exp. Ther.*; 187: 211–217.
25. O'BRIEN, P.J.; SLAUGHTER, M.R.; SWAIN, A.; BIRMINGHAM, J.; GREENHILL, R.; ELCOCK, F. AND BUGELSKI, P.J. (2000): Repeated acetaminophen dosing in rats: adaptation of hepatic antioxidant system. *Human & Experimental Toxicology*; 19: 277-283.
26. PARK, B.; KITTERINGHAM, N. R.; PIRMOHAMED, M. AND TUCKER, G.T. (1996): Relevance of induction of human drug-metabolizing enzymes: pharmacological and toxicological implications. *British J. Clin. Pharmacol.*; 41(6): 477-491.
27. PEARSE, A. G. (1972): *Histochemistry, theoretical and applied*. Third ed.vol 11, Little, Brown& com. Boston.
28. RADY, M. I. (2001): Histological and histochemical study on the protective effect of the iron chelator desferrioxmine against aminoglycosides-induced hepatotoxicity in young rats. *Al-Azhar Bull. Sci.*; 12(2): 247- 265.
29. RIORDAN, S. AND WILLIAMS, R. (2002): Alcohol exposure and paracetamol-induced hepatotoxicity. *Taylor & Francies*; 7(2): 191-206.
30. RITTER, E. J. (1977): *Altered Biosynthesis*. In: *Handbook of Teratology*. Vol.2 Plenum Press, New York.
31. ROCHA, G.; MICHEA, L.; PETERS, E. AND KIRBY, M. (2001): Direct toxicity of nonsteroidal anti-inflammatory drugs for renal medullary cells. *Proc. Natl. Acad. Sci. USA*; 98(9): 5317-5322.
32. SATO, C. AND ISUMI, N (1989): Mechanism of increased hepatotoxicity of acetaminophen by simultaneous administration of caffeine in the rat. *J. Pharmacol. Exp. Ther.*; 248(3): 1243- 1247.
33. SCHLEGEL, R.; CROY, R. AND PARDEE, A. (1987): Exposure to caffeine and suppression of DNA replication combine to stabilize the proteins and RNA required premature mitotic events. *J. Cell Physiol.*; 131(1): 85-91.
34. SENDECOR, G. W. (1987): *Statistical Methods* 6<sup>th</sup> ed. Iowa State Univ. Press.

35. SIMMONS, D.L.; BOTTING, R.M. AND HLA, T. (2004): Cyclooxygenase isozymes: the biology of prostaglandin synthesis and inhibition. *Pharmacol. Rev.*; 56: 387-437.
36. STEGMANN, H.; BURGERMEISTER, W.; SHSH, A.; FRANCKSEN, H. AND KROGERRCKLENFORT, F. (1988): Gel electrophoresis between glass plates in polyacrylamide or other gels. Righetti/Vanoss /Vanderloff eds., Elsevier, Amsterdam.
37. WAHBA, S. R. AND ZIADA, I. A. (1992): Nicotine and caffeine induced on hepatic glycogen levels in rat. *Egypt. J. Histol.*; 15 (2); 419- 430.

## الملخص العربي

دراسة هستولوجية , هستوكيميائية و الفصل الكهربى لبروتينات مصل الدم لتأثير الباراسيتامول والكفايين كمركب على كبد إناث الجرذان

محمد ابراهيم راضى

قسم علم الحيوان - كلية العلوم - جامعة الأزهر

استهدف هذا البحث دراسة تأثير تعاطى الباراسيتامول والكافين كمركب, كشكل مما قد يحدث عند الانسان أحياناً, على كبد اناث الفأر الأبيض وذلك من الناحية هستولوجية والهستوكيميائية وكذلك فحص نمط بروتينات مصل الدم بعد فصله كهريياً. وقد قسمت الفئران الى اربع مجموعات, وضعت المجموعة الأولى كمجموعة ضابطة وعوملت الثلاث مجموعات الأخرى بجرعات مختلفة من المركب لمدة اربعة اسابيع

أثبت الفحص النسيجى للكبد حدوث تغيرات هستولوجية عديدة فى الفئران المعالجة مقارنة بالمجموعة الضابطة, وقد تباينت هذه التغيرات بين الأحتقان والتمدد فى الأوعية الدموية والتجمع للمفاوى وكذلك زيادة ملحوظة لخلايا كوبفر فى المجموعة الثانية والثالثة بينما كانت هذه التغيرات أكثر وضوحاً فى المجموعة الرابعة حيث ظهر التحلل المائى والتحلل النووى والموت الخلوى فى الكثير من الخلايا الكبدية وأيضاً تم ملاحظة الأوديما فى الأوعية الدموية للكبد.

وقد أوضحت الدراسة الهستوكيميائية حدوث نقص معنوى لمحتوى البروتينات فى أكباد فئران المجموعة الرابعة فقط وكان غير معنوي فى كل من المجموعة الثانية والثالثة, وكذلك حدوث نقص معنوي لمحتوى DNA فى كل المجموعات المعالجة. أيضاً بينت النتائج حدوث نقص معنوي لنشاط انزيم الاستيريز الغير متخصص فى المجموعة الثالثة والرابعة بينما كان النقص فى المجموعة الثانية غير معنوي وذلك مقارنة بالمجموعة الضابطة. أحدث هذا المركب أيضاً اختلافاً فى انماط بروتينات مصل الدم فى المجموعات المعالجة مقارنة بالمجموعة الضابطة. وقد تمثلت اساساً هذه التغيرات فى تباين كثافة البروتينات الرئيسية وكذلك ظهور بعض من البروتينات الجديدة, وقد كانت معظم هذه التغيرات مركزة فى مناطق ذات أوزان جزيئية صغيرة.

هذا وقد دلت النتائج المتحصل عليها ان التأثير الناتج عن المعاملة بمركب من الباراسيتامول والكافيين يزداد بزيادة الجرعة, وتؤيد النتائج الاقتراح القائل بأن التأثير الضار للمسكنات قد يزداد نتيجة إضافة الكافيين. لذا يؤكد البحث على أهمية عدم تناول أكثر من دواء فى وقت واحد, وخاصة من المسكنات, مما قد يسبب من اضرار الأتسجة الجسم المختلفة.